

See discussions, stats, and author profiles for this publication at: <https://www.researchgate.net/publication/313663227>

A review of hyperbaric oxygen therapy for avascular necrosis

Article in *Acta Medica Mediterranea* · January 2017

DOI: 10.19193/0393-6384_2017_1_004

CITATION

1

READS

1,336

2 authors:



Ali Erdal Gunes

Harran University

22 PUBLICATIONS 93 CITATIONS

SEE PROFILE



Samil Aktas

Istanbul University, Istanbul Faculty of Medicine

91 PUBLICATIONS 689 CITATIONS

SEE PROFILE

A REVIEW OF HYPERBARIC OXYGEN THERAPY FOR AVASCULAR NECROSIS

ALI ERDAL GUNES*, SAMIL AKTAS**

*Harran University School of Medicine, Underwater and Hyperbaric Medicine Department, Turkey - **Istanbul University Istanbul School of Medicine, Underwater and Hyperbaric Medicine Department, Turkey

ABSTRACT

Introduction: Avascular necrosis (AN) is the death of trabecular bone and bone marrow. Hyperbaric oxygen (HBO) treatment in the early stages of AN of the femoral head alleviates intraosseous pressure by increasing the tissue oxygen pressure, increases micro-circulation by arranging the venous drainage, so is recommended for that patients' treatment plan. Recently, many clinical trials and experimental studies were conducted about the effects of HBO on AN.

Aim: Current treatment modalities partially address a need for adequate remedy to this disease. Prosthetic surgery performed on patients due to AN may cause some medical problems in long term follow up. HBO treatment can bring a new modality option for AN. There is no much data on the efficacy of HBO therapy on disease healing and delay of implementation of prosthetic implants. The aim of this review was to evaluate and summarize the evidence for application of HBO as a treatment for AN.

Methods: The study included 10 randomized studies found in databases including PubMed/MedLine, Science Direct, Web of Science, and Cochrane Central Register of Controlled Trials Databases. The keywords "hyperbaric* oxygen therapy" or "hyperbaric* oxygen treatment" and "avascular necrosis" or "aseptic necrosis" or "femoral head necrosis" were used, and no time frame was selected.

Results: The studies covered in our work consisted of experimental, clinical, and case series assessments. Three were controlled, experimental studies, and seven were clinical trials, which are generally considered more valuable due to their power and study design. Studies were evaluated in three category title; primary outcomes, stage of disease and effectiveness. HBO therapy has been shown to be effective in all three categories.

Conclusion: The incidence of patients with AN is increasing majorly due to some external factors, steroid and trauma. Although the existed literature is qualified, the number of articles about the effects of HBO on AN are still quite few in the electronic database. In order to evidently state the efficacy of HBO in AN, well designed, comprehensive, randomized studies are required.

Keywords: Hyperbaric Oxygenation; Avascular Necrosis of Bone; Aseptic Necrosis of Bone; Femur Head Necrosis.

DOI: 10.19193/0393-6384_2017_1_004

Received September 30, 2016; Accepted November 02, 2016

Introduction

Avascular necrosis (AN) is the death of trabecular bone and marrow, and is primarily observed in femur head⁽¹⁶⁾. The pathogenesis is believed to be caused by the ischemia that occurs with the deterioration of micro-circulation in the femoral head.¹⁷ The annual US incidence of AN is between 10,000 and 15,000⁽²²⁾. The disease most commonly emerges in young adults, with an average age of 38 years.

Prognosis is variable, and the treatment period may be long requiring hospitalization. Early diagnosis and appropriate surgery can reduce the risk of progression and achieve good results⁽²⁶⁾. The presence of femur-head bone marrow edema can be used in early diagnosis of AN⁽¹⁾.

Surgical treatment options are include drilling, core decompression, fibular grafting, and osteotomy⁽²⁶⁾. Non-surgical treatment options include rest, weight loss, pharmacological agents, pulsed elec-

tromagnetic fields, and hyperbaric oxygen (HBO) therapy⁽²⁵⁾. HBO necessitates breathing high level of oxygen under elevated partial pressure⁽⁶⁾. The level of plasma-resolvable oxygen rises within surrounding atmospheric pressure. This augmentation in surrounding pressure means that it can spread toward deep tissues, therefore oxygen reaches tissues even with low blood flow⁽¹⁵⁾. HBO therapy leads to the reduction of local hypoxia and inflammation, improved control of infection, control of edema, reduction of neutrophil adhesion, increased leukocyte activity, and promotion of the synthesis of collagen and blood vessel growth⁽²⁴⁾. It re-introduces tissue oxygenation in the trabecular bone, decreases edema and inflammation, stimulates angiogenesis⁽¹⁷⁾. HBO also decreases intra-osseous pressure, and increases the micro-circulation by re-organizing venous drainage, and its use has been suggested in the treatment plans of people with early-phase AN⁽²³⁾.

Recent studies have shown that the effects of HBO therapy in patients with AN reported successful results⁽³⁻⁴⁾. The aim of this review was to evaluate and summarize the evidence for application of HBO as a treatment for AN.

Materials and method

Search Strategy

Publications were accessed via well-known electronic databases including PubMed/MedLine, Science Direct, Web of Science, Cochrane Central Register of Controlled Trials and Databases. The keywords “hyperbaric* oxygen therapy” or “hyperbaric* oxygen treatment” and “avascular necrosis” or “aseptic necrosis” or “femoral head necrosis” were used, and no time frame was selected. HBO therapy is given to patients in multiple sessions, that is, more than one session, and is usually given for 2 hours on a daily basis.

Inclusion criteria

We included all studies, adult and pediatric, found on the databases regarding HBO therapy in AN. No type of work-type filter was applied while choosing the studies. Studies given as adjunctive therapy of HBO treatment were included too. Studies were included if they reported in terms of efficacy on “MRI assessment, stage of disease, surgical treatment, and long-term follow up”.

Exclusion Criteria

Studies involving patients receiving other types of treatments, such as only surgical or only pharmacological treatments, were excluded. Only original articles were included, so the letters, commentaries, conference summaries and restricted reviews were all excluded.

Data Extraction

Data were classified based on the name(s) of the author(s), study design, year of publication, disease stage of the patient population, number of patients, follow-up period in the clinical study, and all data related to the defined outcomes. Eighteen studies identified through the database search. Three records removed because of duplication. We reached the full text of fifteen records. Five of the fifteen articles excluded with the following reasons: letter content, giving general information for HBO without providing sufficient details about HBO therapy. Three of the ten studies were consisted of experimental controlled studies, four of them were clinical case series and three of them were clinical controlled studies. The number of records identified, included and excluded was stated by PRISMA flow diagram (Figure 1).

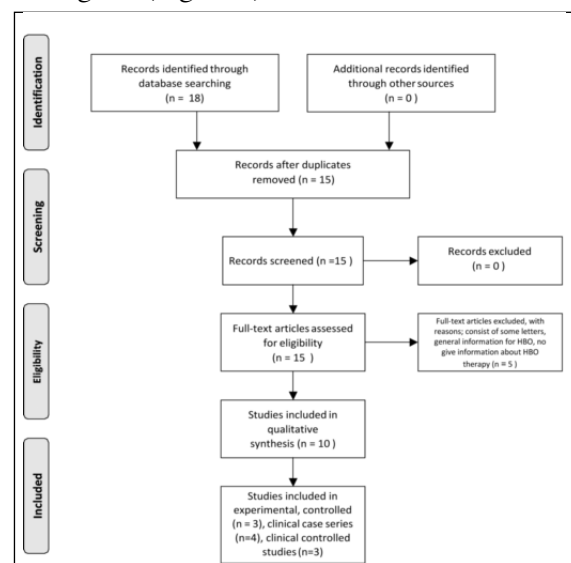


Figure 1: Study current diagram.

Results

After scanning the aforementioned databases, we found 10 studies that reviewed the effect of HBO therapy in people diagnosed with AN. The studies consisted of experimental, clinical, and case series assessments.

Three were controlled, experimental studies, and seven were clinical trials, which can be considered valuable. When we classified these publications, we found that three were randomized, controlled, experimental studies, while the three were clinically controlled, prospective, randomized studies. Only one of the clinically controlled studies was reported as being double-blind. The remaining four of total studies were serial case studies, but one of them was not controlled (Table 1).

macological treatment to control groups, and Scherer compared HBO treatment with NWB. In terms of HBO treatment modalities, the studies carried out by Zhao, Reis, and Huri were similar to that conducted by Scherer.

The studies recently conducted by Camporesi⁽³⁾, Capone⁽⁴⁾ and Hsu⁽⁷⁾ included a total of 159 patients and were analyzed as controlled clinical trials. Hsu included HBO in a cocktail of treatment compared with extra-corporeal shock wave

Author	Year	Giving Treatments		Study Type	Number of subjects		Effect of HBO therapy	Follow-up duration
					HBO	Other		
Levin ¹³	1999	HBO	NGT	Experimental, Controlled	26	18	Significant(p<0.01)	6 weeks
Peskin ¹⁸	2001	HBO	NWB	Experimental, Controlled	16	38	Significant(p<0.01)	4-6 weeks
Kataoka ¹²	1992	HBO	NGT	Experimental, Controlled	20	20	Significant(p<0.01)	17 weeks
Zhao ²⁷	2010	HBO	PG E1, Ipratropine and Salvia Miltiorrhiza	Clinical, Case series ARCO Stage 1-2	84	-	Significant(p<0.05)	4 years
Huri ¹⁰	2011	HBO	-	Clinical, Case series FICAT Stage 1-2a	4	-	Significant(p<0.01)	1 year
Reis ¹⁹	2003	HBO	-	Clinical, Case series Steinberg Stage 1	16	-	Significant(p<0.01)	From 2 years to healing
Scherer ²⁰	2000	HBO+NWB	NWB	Clinical, Case series Early treatment of chemotherapy	12	8	Significant(p<0.05) about osteoedema	3-76 months
Hsu ⁷	2010	HBO+ESW T+Alendronat	ESWT	Clinical, Controlled ARCO Stage 1-2-3	50	48	Not significant(p>0.05)	1 year
Camporesi ³	2010	HBO	HBA	Clinical, Controlled, Randomized, Double blind Ficat Stage 2	10	10	Significant(p<0.01) about clinical improvement	7 years
Capone ⁴	2011	HBO+NWB + Pharmacologic	NWB+ Pharmacologic	Clinical, Controlled %50 MRI Stage 4	21	20	Significant(p<0.03)	2 years

Table 1: Included studies with primary outcomes.

HBO: Hyperbaric Oxygen Therapy; NWB: Non- Weight Bearing; HBA: Hyperbaric air; NGT: No Giving Treatment; ESWT: Extra-corporeal Shock Wave Treatment; PG: Prostaglandin; ARCO: Association Research Circulation Osseous; (p< 0,05 is significant)

Primary Outcomes

No trials specifically reported complete resolution of AN. Kataoka⁽¹²⁾, Levin⁽¹³⁾ and Peskin⁽¹⁸⁾ examined the efficacy of HBO therapy in controlled, experimental studies in 138 rats. Levin and Kataoka compared a HBO therapy group with a group that did not receive treatment, and Peskin administered non-weight bearing (NWB) treatment to the control group used. The HBO therapeutic modalities used by Levin and Peskin were applied 2.5 ATA in 90 minutes, while Kataoka applied 2.8 ATA in 60 minutes.

In this study analyzed the clinical range used in the studies conducted by Huri⁽¹⁰⁾, Reis⁽¹⁹⁾, Scherer⁽²⁰⁾ and Zhao⁽²⁷⁾ which included 116 patients. Huri and Reis did not administer treatment to the control groups they used, whereas Zhao gave phar-

macological treatment to control groups, and Scherer compared HBO treatment with NWB. In terms of HBO treatment modalities, the studies carried out by Zhao, Reis, and Huri were similar to that conducted by Scherer.

The studies recently conducted by Camporesi was the sole researcher involved in one randomized controlled double-blind study that compared HBO therapy with hyperbaric air treatment.

Capone added HBO to NWB and pharmacological therapy for comparison. The patients with all groups received 20, 30, and 40 sessions of HBO treatment after measurements were made.

Stage of Disease: None of the experimental studies contained information regarding the phases of the disease in rats. Rats with experimentally established AN had been treated after the administration. They had early-stage disease, with respect to the classification of the Association Research Circulation Osseous(ARCO), Steinberg, and Ficat, with the exception of Capone and Hsu. Capone, according to MRI classification, determined that

50% of patients were stage 4, while 32 of 98 patients in the Hsu study were ARCO stage 3. The Scherer study used MRI scoring and planned early chemotherapy treatment.

Effectiveness: In their experimental studies, Kataoka⁽¹²⁾, Levin⁽¹³⁾ and Peskin⁽¹⁸⁾ observed a significant improvement in the HBO treatment group. They have followed the working group for 17 weeks. Huri⁽¹⁰⁾, Reis⁽¹⁹⁾ and Zhao⁽²⁷⁾ observed clinically significant improvements in their HBO series, but Scherer⁽²⁰⁾ has evaluated only significant improvement in the osteoedema at early stage of AN. Zhao and Scherer followed patients up for an average of 4 years, and Huri for 1 year; but Reis was followed two years or until healing.

In the controlled clinical trials reported by Hsu, no significant improvement was observed with HBO treatment in approximately 30% of patients with advanced stage disease in the 1-year follow-up. Camporesi⁽³⁾, who conducted a randomized, controlled and double-blind study, stated that a clinically remarkable improvement was only observed in those patients with the longest follow-up period (7 years). In the Capone⁽⁴⁾ study, although MRI showed that approximately 50% of patients had stage 4 disease, there was a significant improvement in the HBO treatment group.

Discussion

Fibrotic barriers worsen the progression of osteonecrosis by inhibiting neovascularization and necrotic tissue healing. HBO therapy increases partial oxygen pressure in plasma, and more oxygen dissolves. As the amount of oxygen dissolved in plasma increases, the diffusion distance of oxygen increases in the tissue urging collagen synthesis, fibroblast proliferation, and capillary angiogenesis^(9,14). AN is also associated with intra-osseous pressure buildup, which causes bone marrow edema⁽²¹⁾. In these cases, it has been shown that venous hypertension and poor venous drainage affects the femur head⁽⁸⁾. HBO increases perfusion and decreases edema, therefore, by reducing intra-osseous pressure, HBO rapidly improves microcirculation⁽⁵⁾. With high oxygen pressure, mesenchymal stem cells differentiate into osteoblasts⁽²⁾, the cells with high metabolic rate, and destroy the oxygen-dependent necrotic bone tissue. They decrease bone density and remodel the tissue by increasing the hyper oxygenation activity of osteoclasts⁽¹¹⁾.

Easy surveillance of the MRI scans of the

patients allowed us to obtain accuracy regarding with the prognosis and treatment efficacy. Although AN is more common in young adults, it may also be observed in children as a complication of other diseases. The literature on pediatric cases is very poor. The study conducted by Scherer is the only pediatric assessment that is available in the databases⁽²⁰⁾. Further studies are required in order to identify a treatment for this disease in children and to obtain an idea of the prognosis.

Experimental studies and clinical studies conducted in people diagnosed with AN have shown that HBO therapy greatly improves disease prognosis and delays invasive surgical interventions. Very few studies have shown that HBO therapy is less effective than other treatment methods^(7,20). Numerous studies have attempted to obtain objective results by conducting medical treatment trials^(4,7,10,27). Some researchers have stated that long-term surveillance of patients showed that the recovery from AN continues for many years in young adults following HBO treatment, and that surgical interventions should be considered at a later stages^(3,27).

Experimental studies are important to elucidate the effects of HBO on necrosis treatment methods. These studies have reported different effects of HBO therapy on avascular necrosis. Levin asserted that HBO should be administered 4-6 hours after AN injury, while Peskin started the treatment 5 days after such an injury. Levin did not find a difference in improvement on postoperative days, but the histological studies showed an improvement in the HBO group on the second day. Accordingly, Peskin observed that recovery primarily occurs between 30 and 42 days, in terms of the amount of necrotic debris, new bone formation, and joint cartilage. Kataoka stated that two groups of rats that received HBO therapy significantly improved ($p < 0.04$, $p < 0.01$), and asserted that this treatment had increased ossification^(12,13,18).

Considering the long-term continuation of recovery, the studies conducted by Zao and Reis are very informative. The MRI findings of patients improved to normal in the Reis study. Zao conducted the longest and most comprehensive study of AN, and showed that AN progresses in a time-dependent manner. If the case is at advanced stage, surgical intervention is used. In this study, no control group was used to counteract bias^(19,27).

The databases contained no studies that had been designed to assess patients with advanced

stage AN. In the clinical studies, only Hsu selected patients classified as ARCO grades 1, 2 and 3. There is information describing the number of patients chosen, and at which state, and in which group; 32 of 98 had grade 3 AN. However, no statistically significant difference was observed in improvement after HBO therapy ($p > 0.05$)⁽⁷⁾. Scherer created his own AN evaluation score in his pediatric study, which was not counted as early stage. Consequently, there was no statistically significant distinction in improvement disease outcome between the two groups except osteoedema ($p > 0.05$)⁽²⁰⁾. Half of the 41 patients in the Capone study were stage 4, according to their MRI classification. HBO therapy produced statistically significant improvement ($p < 0.01$)⁽⁴⁾. Camporesi stated that the HBO affect is weak in patients who are at an advanced stage, because of the collapse of the joint⁽³⁾. Only one study has found that HBO resulted in statistically significant improvements in the advanced stage of AN.4 However, no study on the efficacy of HBO in the advanced stages of AN can currently be found in the databases.

Conclusion

Implications for Clinical Studies: Overall, AN is more common in young adults, and life expectancy is long. Although some evidence suggests that HBO may be effective in the early stage of AN, this positive role may be in pain alleviation. In addition, osteoedema can be improved by HBO therapy. However, there is inadequate evidence of the efficacy of HBO in patients in the advanced stage of AN to support its use in these individuals. The use of HBO as a preventive therapy for AN is not supported by the evidence.

It is recommended that HBO be considered as a complement to, or before, surgery, or used to support medical treatments. It has been shown that if HBO therapy is implemented in the early stages of treatment, it can be efficient in movement mechanism and prevent joint collapse situations, and MRI may return to normal view. It has been stated that in the advanced stages of the disease, and in situations such as collapsed joints, surgery must be considered as the first option.

Implication for investigations: Since the improvement continues long-term, it is important to maintain HBO therapy on a long-term basis to improve prognosis. As a result of difficulties experienced in daily life, pain control should be admin-

istered to these young patients. Although the number of AN cases has increased, depending on external factors, steroids, and trauma, the number of HBO publications in the electronic databases, despite being of high quality, are few. Further experimental and clinical studies, an increased experience of treatment, and the addition of HBO protocols to the treatment plan will provide new research opportunities. With additional studies, the role of HBO therapy can be better understood with histological and biochemical diagnostic methods.

The findings of this review showed that there is a substantial need for further studies with large number of patients, investigation of HBO as a feasible treatment for AN and bone marrow edema in addition to the standard treatment modalities. The confirmation of the effectiveness of HBO as a primary treatment in a well-designed, controlled study with sufficient patient long follow-up is essential to produce valuable conclusions. The effect of implementation of HBO modality to other therapies administered simultaneously or adjunctively is not well known nor its pure effect parting of other therapies. The studies have shown that HBO treatment delayed surgical operations in the early stages of AN. Although these results show efficacy of HBO treatment at some degree, well-planned and multicentric studies are needed to determine the effective dose of the treatment, and to demonstrate the long-term and cost-benefit effects of HBO treatment.

References

- 1) Asher MA, Sledge CB. Hyperoxia and in-vitro bone resorption. *Clinical orthopaedics and related research*, 1968, 61: 48-51.
- 2) Bassett CA, Herrmann I. Influence of oxygen concentration and mechanical factors on differentiation of connective tissues in vitro. 1961: 460-461.
- 3) Camporesi EM, Vezzani G, Bosco G, Mangar D, Bernasek TL. Hyperbaric oxygen therapy in femoral head necrosis. *The Journal of arthroplasty*, 2010, 25.6: 118-123.
- 4) Capone A, Podda D, Ennas F et al. Hyperbaric oxygen therapy for transient bone marrow oedema syndrome of the hip. *Hip International*, 2011, 21.2.
- 5) Ficat P, Grijalvo P. Long-term results of the forage-biopsy in grade I and II osteonecrosis of the femoral head. Apropos of 133 cases re-examined after an average time of 9 years 6 months. *Revue de chirurgie orthopedique et reparatrice de l'appareil moteur*, 1983, 70.3: 253-255.
- 6) Gesell LB. Hyperbaric oxygen therapy indications: The Hyperbaric Oxygen Therapy Committee report.

- Undersea and Hyperbaric Medical Society, 2008.
- 7) Hsu, S. L, Wang, C. J, Lee, M et al. Cocktail therapy for femoral head necrosis of the hip. Archives of orthopaedic and trauma surgery, 2010, 130.1: 23-29.
 - 8) Hungerford DS. One-Marrow Pressure, Venography, And Core Decompression In Ischemic Necrosis Of The Femoral-Head. Orthopade, 1980, 9.4: 245-254.
 - 9) Hunt TK. The effect of varying ambient oxygen tensions on wound metabolism and collagen synthesis. Surg Gynecol Obstet, 1972, 135: 561-567.
 - 10) Huri G, Dundar K, Iyetin Y, Doral MN. Erken evre femur basi avaskuler nekrozlu olgularda hiperbarik oksijen tedavisi. Goztepe Tip Dergisi, 2011; 26(3):108-111.
 - 11) Jones JP, et al. The effect of hyperbaric oxygen on osteonecrosis. 1991. Orthopaedic Research Society: Anaheim, CA.
 - 12) Kataoka, Y, Hasegawa Y, Iwata H et al. Effect of hyperbaric oxygenation on femoral head osteonecrosis in spontaneously hypertensive rats. Acta Orthopaedica Scandinavica, 1992, 63.5: 527-530.
 - 13) Levin D, Norman D, Zinman C et al. Treatment of experimental avascular necrosis of the femoral head with hyperbaric oxygen in rats: histological evaluation of the femoral heads during the early phase of the reparative process. Experimental and molecular pathology, 1999, 67.2: 99-108.
 - 14) Marcus ND, Enneking WF, Massam RA. The silent hip in idiopathic aseptic necrosis. J Bone Joint Surg Am, 1973, 55.7: 1351-1366.
 - 15) Marx RE, Ehler WJ, Tayapongsak P, Pierce LW. Relationship of oxygen dose to angiogenesis induction in irradiated tissue. The American Journal of Surgery, 1990, 160.5: 519-524.
 - 16) Mazieres B. Osteonecrosis. Rheumatology, 1994, 2: 1877-1890.
 - 17) Nylander G, Lewis D, Nordstrom H, Larsson J. Reduction of posts ischemic edema with hyperbaric oxygen. Plastic and reconstructive surgery, 1985, 76.4: 596-601.
 - 18) Peskin B, Shupak A, Levin D et al. Effects of non-weight bearing and hyperbaric oxygen therapy in vascular deprivation-induced osteonecrosis of the rat femoral head. Undersea & hyperbaric medicine, 2001, 28.4: 187.
 - 19) Reis ND, Schwartz O, Militianu D et al. Hyperbaric oxygen therapy as a treatment for stage-I avascular necrosis of the femoral head. Bone & Joint Journal, 2003, 85.3: 371-375.
 - 20) Scherer A, Engelbrecht V, Bernbeck B et al. MRI evaluation of aseptic osteonecrosis in children over the course of hyperbaric oxygen therapy. In: Röntgenfortschritte auf dem Gebiet der Röntgenstrahlen und der bildgebenden Verfahren. © Georg Thieme Verlag Stuttgart: New York, 2000. p. 798-801.
 - 21) Schroer WC. Current concepts on the pathogenesis of osteonecrosis of the femoral head. Orthopaedic review, 1994, 23.6: 487-497. 22
 - 22) Solacoff D, Mont MA, Krackow KA. Uncemented total hip arthroplasty in patients less than 45 years with avascular necrosis. Orthop Trans, 1993-1994;17:1085.
 - 23) Strauss M, Dvorak T, Melamed Y et al. Femoral head necrosis and hyperbaric oxygen therapy. Kindall EP, Whelan HT. Hyperbaric Medicine Practice. St Louis. Best Publishing Co, 1999, 912.
 - 24) Thom SR. Oxidative stress is fundamental to hyperbaric oxygen therapy. Journal of applied physiology, 2009, 106.3: 988-995.
 - 25) Wang C, Peng J, Lu S. Summary of the various treatments for osteonecrosis of the femoral head by mechanism: A review. Experimental and Therapeutic Medicine. Sep 2014; 8(3): 700-706.
 - 26) Yoo MC, Kim KI, Hahn CS, Parvizi J. Long-term follow up of vascularized fibular grafting for femoral head necrosis. Clin Orthop Relat Res. May 2008; 466(5): 1133-1140.
 27. Zhao FC, Li ZR, Zhang NF et al. Lesion size changes in osteonecrosis of the femoral head: a long-term prospective study using MRI. International orthopaedics, 2010, 34.6: 799-804.

*** This article, has been accept as a verbal panel presentation at the 7. National Underwater and Hyperbaric Medicine Congress of Turkey.*

Corresponding author

Asst. Prof. ALI ERDAL GUNES
Harran University School of Medicine
Department of Underwater and Hyperbaric Medicine
Yenisehir Campus, 63300, Sanliurfa
(Turkey)